

VETGOLD CASE REPORT:

Case # 5

Patient: Name: Marlowe **Breed:** Male, Canine, Dalmatian

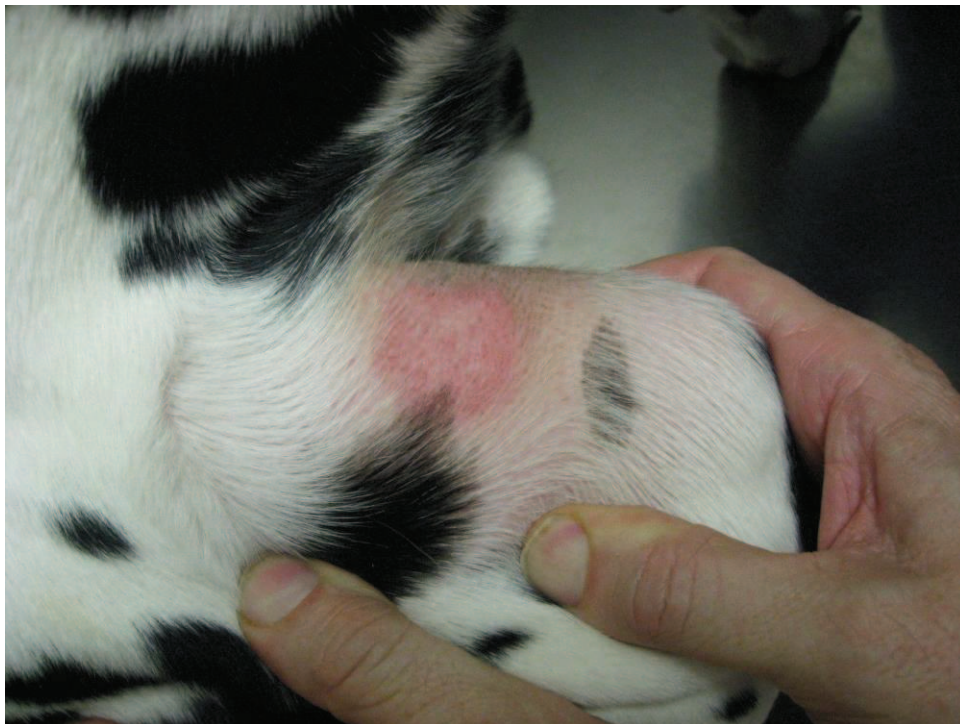
Condition: Acute Moist Dermatitis, "Hotspot"

Symptoms: Severe irritation, licking, infection of skin of leg

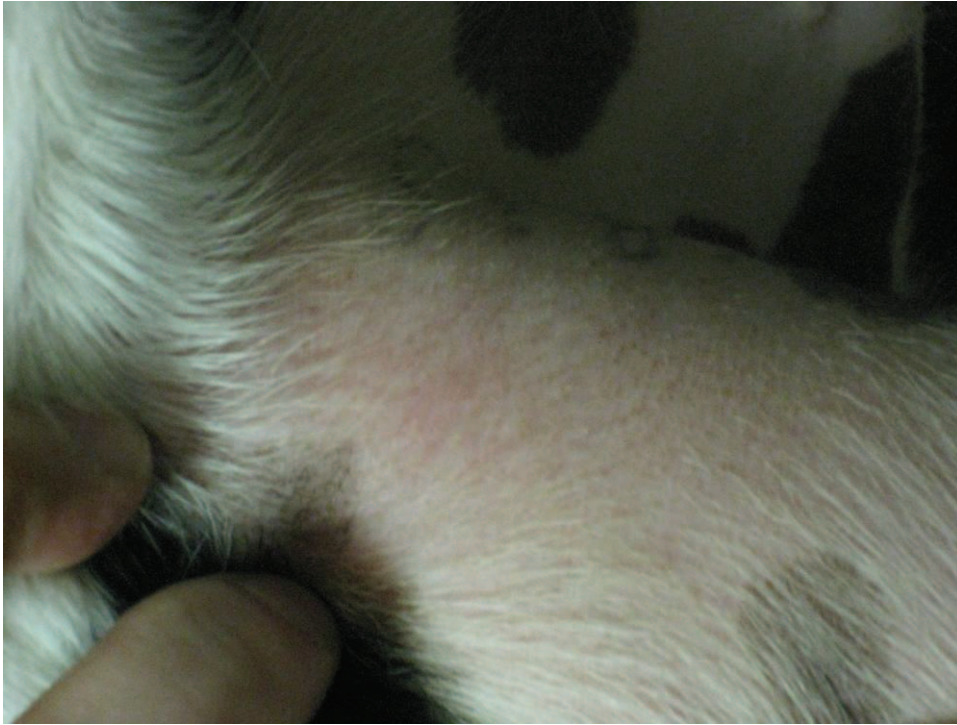Treatment:

Treatment with VETGOLD application to area twice daily

Date: Started applying Vetgold



7 Days after starting Vetgold Application



Results & Recommendations:

Lesion was fully healed after 7 days

Dr Mark Teeger BSc BVsc
Dr Mike Cormier DVM
Mr Bruce Wulfsohn
NVP Canada